

Kounis Syndrome Due to SARS-CoV-2 Vaccination: A Case Report

Tomohisa Tokura^{*}, Akihide Konn

Department of Critical and Emergency Medicine, Hachinohe City Hospital, Hachinohe City, Japan

Email address:

hiromudaichi@yahoo.co.jp (Tomohisa Tokura), hotate1@nifty.com (Akihide Konn)

^{*}Corresponding author

To cite this article:

Tomohisa Tokura, Akihide Konn. Kounis Syndrome Due to SARS-CoV-2 Vaccination: A Case Report. *Clinical Medicine Research*. Vol. 11, No. 6, 2022, pp. 159-162. doi: 10.11648/j.cmr.20221106.12

Received: October 18, 2022; **Accepted:** November 12, 2022; **Published:** November 22, 2022

Abstract: *Background:* The SARS-CoV-2 vaccine is a major player in the global coronavirus disease 2019 COVID-19 pandemic response. The frequency of anaphylaxis due to the SARS-CoV-2 vaccination (COMIRNATY intramuscular injection®) is reported to be higher than initially described. Herein, we describe a case of acute myocardial infarction after anaphylaxis (Kounis syndrome) following vaccination. The reasons why we report this case is to call for caution when considering vaccination. Health care providers need to be aware of these side effects and be informed on how to best treat these side effects. *Case Presentation:* A 97-year-old woman developed coughing and wheezing a few minutes after she received her first COMIRNATY intramuscular injection®. She was diagnosed with anaphylaxis and was administered intramuscular epinephrine. Two days later, a twelve-lead electrocardiogram showed new broad ST segment depression and atrial fibrillation; elevated cardiac enzymes were also noted. High levels of WBC, AST, and LDH were elevated on the day following vaccination. She was referred to our hospital and diagnosed with NSTEMI (non-ST-elevation myocardial infarction). On the fourth day of illness, she was discharged. However, she died on the fifth day of illness in the nursing home. *Discussion:* In anaphylaxis, mast cells become activated and degranulate, releasing various inflammatory mediators, which trigger coronary artery spasm or rupture coronary artery plaques. This is referred to as Kounis syndrome. A high CRP value on the day following vaccination suggests the presence of a high inflammatory response due to the release of inflammatory mediators. Since anaphylaxis developed immediately after vaccination and there was no ingestion of other antigens that can cause anaphylaxis, it is obvious that this anaphylaxis was caused by the vaccine. There have been sporadic reports of Kounis syndrome in Japan, but the problem is that this disease is not widely recognized. It is also a problem that there are very few reports of Kounis syndrome due to vaccination. It is assumed that there are many undiagnosed cases. *Conclusions:* We encountered a patient who developed acute myocardial infarction after anaphylaxis, characteristic of Kounis syndrome, due to the SARS-CoV-2 vaccine. Kounis syndrome affects the coronaries arteries, and may have secondary symptoms such as anaphylaxis, respiratory distress and altered blood values. Caution and close follow-up needs to be exercised in patients who develop anaphylaxis after vaccination. Furthermore, the risks and side effects of the vaccine should be acknowledged.

Keywords: Kounis Syndrome, SARS-CoV-2 Vaccination, Anaphylaxis, Acute Myocardial Infarction

1. Introduction

The coronavirus disease 2019 (COVID-19) pandemic is influencing daily clinical practice greatly. The development of the SARS-CoV-2 vaccine has been a major player in the global pandemic response.

The development of vaccinations for COVID-19 has progressed, and a number of approved vaccines are currently

being administered to patients worldwide to improve prognosis, reduce the severity of disease, and reduce the effect of COVID-19 on patient life. However, vaccination is not without its side effects.

The frequency of anaphylaxis due to SARS-CoV-2 vaccine “COMIRNATY intramuscular injection®” was reported by Pfizer Inc. to be 4.7 cases per million vaccinations. However, it was reported by the Ministry of Health, Labour and Welfare in Japan to be 18.5 cases per million vaccinations if suspected

cases were included, indicating that the rate of anaphylaxis might be higher than initially reported [1].

We encountered a patient who developed acute myocardial infarction after anaphylaxis (Kounis syndrome) due to SARS-CoV-2 vaccine. One of the reasons why we report this case is to call for caution when considering vaccination. Notably, side effects can occur following SARS-CoV2 vaccination. Health care providers need to be aware of these side effects and be informed on how to best treat these side effects.

2. Case

Patient: A 97-year-old woman

Chief complaint: Loss of appetite.

Past medical history: hypertension, diabetes, and depression.

Life history: She was a resident of special nursing home for the elderly. She required a wheelchair to perform her activities

of daily living.

History of present illness: A few minutes after the patient was vaccinated with COMIRNATY intramuscular injection® for the first time by her primary care physician, she started coughing and wheezing. Adrenaline 0.3 mg was injected intramuscularly to her 3 times, and her symptoms improved. She was being observed in the special nursing home for the aged. Two days later, blood tests showed increased WBC (White blood cell) at 16400/ μ L and increased CK (Creatine kinase) at 653 IU/L. A 12-lead electrocardiogram yielded abnormal findings as well. She was referred to our Emergency and Critical Care Center.

Vital sign: Blood pressure was 150/81 mmHg, heart rate 72/minute, percutaneous oxygen saturation 96% (room air), body temperature 35.9°C, and respiratory rate 16/minute.

Twelve-lead electrocardiography: New broad ST segment depression on II, III, aVF, and V2 to V5 leads as well as atrial fibrillation were noted (Figures 1 and 2).

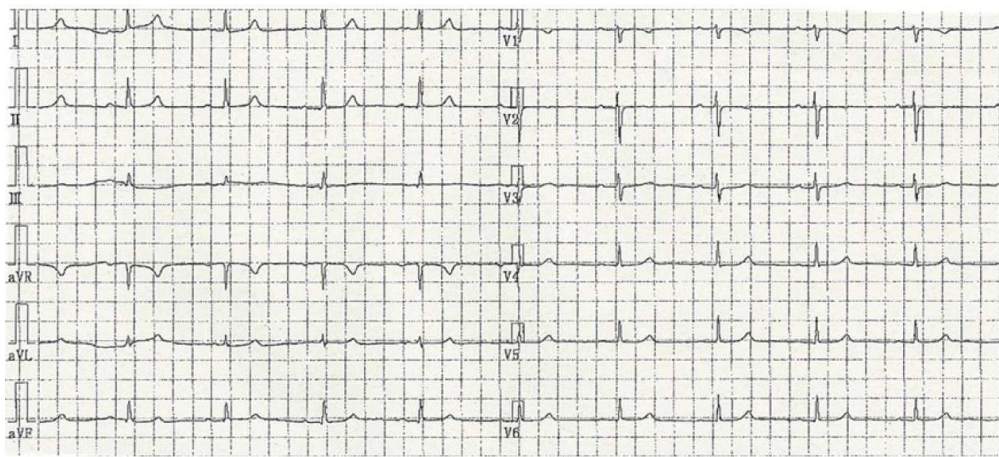


Figure 1. Electrocardiogram (two years ago): There were no ST-T changes.

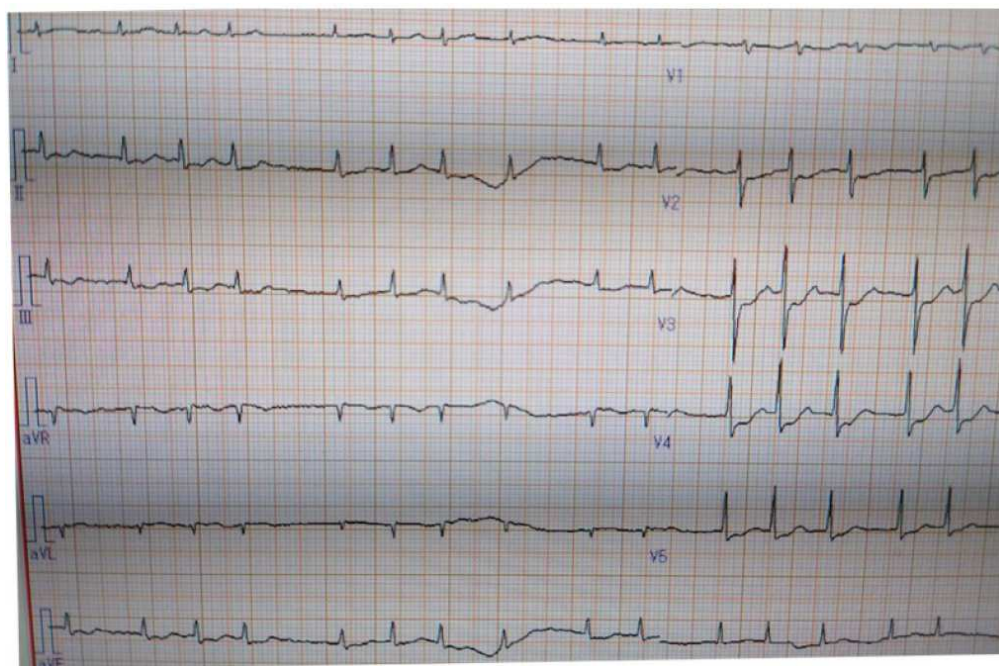


Figure 2. Electrocardiogram (on admission): There were new ST changes in II, III, aVF and V2 to V5 with atrial fibrillation.

Table 1. Blood test (time series): CK and CK-MB were high on admission. These test results were improved over time.

	Next day (Vaccine)	Two days later (admission)	Day 2	Day 4
WBC (/μl)	18000	14800	12000	9400
CK (U/l)	-	552	387	272
CK-MB (U/l)	-	32	20	11
CPR (mg/dl)	9.83	4.18	3.45	3.71
AST (U/l)	113	70	54	42
LDH (U/l)	954	833	716	510

Blood test findings: CK and CK-MB were elevated. In addition (Table 1), troponin T was high at 47.04 ng/mL.

Echocardiography: EF was decreased at 40%, and hypokinesis of the left ventricular anterior and lateral walls was noted.

Disease course after hospitalization: On the basis of the above test results, the patient was diagnosed with NSTEMI (non-ST-elevation myocardial infarction). Her medical team recommended cardiac catheterization, but neither she nor her family agreed to aggressive treatment. Therefore, she was managed conservatively, primarily with dual antiplatelet therapy.

No subsequent chest symptoms developed, and cardiac enzymes were decreased. On the fourth day of illness, she was discharged. However, she died on the fifth day of illness in the nursing home.

3. Discussion

It has been proved that, in anaphylaxis, mast cells become activated and degranulate, releasing various inflammatory mediators, which trigger coronary artery spasm or rupture coronary artery plaques. This is referred to as Kounis syndrome [2-6].

Kounis syndrome is largely classified into 3 types according to the status of coronary arteries before onset: Type I has no significant stenosis in coronary arteries, but allergic reaction triggers coronary spasm resulting in ACS (Acute coronary syndrome). Type II has significant stenosis in coronary arteries, and coronary spasm is triggered resulting in ACS. Type III develops stent thrombosis after coronary stent placement [7, 8].

This patient developed anaphylaxis after SARS-CoV-2 vaccination. A high CRP (C-reactive protein) value in blood tests on the day following vaccination suggests the presence of a high inflammatory response due to the release of inflammatory mediators. Although a cardiac catheter test was not performed, WBC, AST (Aspartate aminotransferase), and LDH (Lactate dehydrogenase) were elevated on the day following vaccination. Therefore, anaphylaxis may have caused coronary artery spasm or rupture of coronary artery plaques, resulting in the development of acute myocardial infarction (Kounis syndrome). Many unknown factors may have influenced patient death. Considering underlying diseases such as hypertension and diabetes, however, the patient may have had coronary artery stenosis before Kounis syndrome and developed reinfarction [9-11].

Although there have been sporadic reports of Kounis syndrome in Japan [12], this disease is not widely recognized.

Therefore, we presume that there are many undiagnosed cases.

There have been very few reports of Kounis syndrome caused by vaccination like this case, and only a small number of cases caused by the influenza vaccine and tetanus vaccine have been reported [13, 14]. Since anaphylaxis developed immediately after vaccination and there was no ingestion of other antigens that can cause anaphylaxis, it is obvious that this anaphylaxis was caused by the vaccine, and we believe that possible association with coronary artery spasm cannot be ruled out.

According to a focused survey (cohort survey) in the early phase after the start of administration of COMIRNATY intramuscular injection®, 1 case of acute myocardial infarction occurred among 19,807 vaccinees [15].

There was no article that investigated the frequency of acute myocardial infarction due to COMIRNATY intramuscular injection®, but, according to the Vaccine Adverse Event Reporting System (VAERS) Results published by CDC (Centers For Disease Control and Prevention), as of March 4, 2022, 449 cases of acute myocardial infarction was reported among 358,398 patients vaccinated with COMIRNATY intramuscular injection® (0.13%), which is much higher than the value described in the report mentioned prior [15]. The VAERS is a system in which patients self-report side effects. Therefore, it is not statistically accurate, and causal relationships were not proved. However, the frequency of clinical acute myocardial infarction may be higher than that in the focused survey in the early phase after the start of administration. We believe that monitoring for acute myocardial infarction after anaphylaxis due to vaccination with COMIRNATY intramuscular injection® is advisable due to the acute clinical course and adverse morbidity of Kounis syndrome.

4. Conclusion

We report a case of Kounis syndrome due to vaccination for coronavirus disease 2019. Kounis syndrome affects the coronaries arteries, and may have secondary symptoms such as anaphylaxis, respiratory distress (coughing and weezing), and altered blood values (CRP, LDH, WBC, and AST). Kounis syndrome is very rare; however, cases of Kounis syndrome following SARS-CoV-2 vaccination with COMIRNATY intramuscular injection® has occurred. Those administering the COMIRNATY intramuscular injection® should be aware of the Kounis syndrome symptoms and informed of the proper treatment modalities. Furthermore, acknowledgement of the risks of SARS-CoV-2 vaccination deserves attention.

Acknowledgements

We would like to thank Editage (www.editage.com) for English language editing.

References

- [1] The Ministry of Health, Labour and Welfare: The Subcommittee Meeting on Drug Safety of the Committee on the Drug Safety of Pharmaceutical Products of the 28th Pharmaceutical Affairs and Food Sanitation Council. Reported cases of suspected adverse drug reactions: February 18, 2022 (in Japanese).
- [2] Kounis NG, Koniari I, Velissaris D, et al: Kounis: Kounis syndrome-not a Single-organ Arterial Disorder but a Multisystem and Multidisciplinary Disease. *Balkan Med J* 2019; 36: 212-21.
- [3] Kounis NG, Hahalis G, Manola A, et al: Kounis syndrome (allergic angina and allergic myocardial infarction). *Angina pectoris: etiology, pathogenesis and treatment*. Nova Science Publishers, New York, 2008, p 77-150.
- [4] Kounis NG, Zavras GM: Histamine-induced coronary artery spasm: the concept of allergic angina. *Br J Clin Pract*. 1991; 45: 121-8.
- [5] Kounis NG. Kounis syndrome: an update on epidemiology, pathogenesis, diagnosis and therapeutic management. *Clin Chem Lab Med* 2016; 54: 1545-59.
- [6] Kounis NG. Kounis syndrome (allergic angina and allergic myocardial infarction): a natural paradigm? *Int J Cardiol* 2006; 110: 7-14.
- [7] Kounis NG, Mazarakis A, Tsigkas G, et al: Kounis: Kounis syndrome: a new twist on an old disease. *Future Cardiol*. 2011; 7: 805-24.
- [8] Kounis NG, et al: Kounis syndrome. *Future Cardiol*. 2011; 7: 805-24.
- [9] Subhankar C, Umesh Ojha, Bhagya V: Myocardial infarction after COVID-19 vaccination-casual or causal? *Diabetes & Metabolic Syndrome: Clinical Research & Reviews* 2021; 15: 1055-1056.
- [10] Boivin Z, Martin J.: Untimely myocardial infarction or COVID-19 vaccine side effect. *Cureus* 2021; 13: 13651.
- [11] Kounis NG, Koniari I, De Gregorio C, et al: Allergic reactions to current available COVID-19 vaccinations: pathophysiology, causality, and therapeutic considerations. *Vaccines* 2021; 9: 221.
- [12] Takeshi Haoka, Yuka Morishita, Yuki Naito, et al: kounis syndrome presenting with anaphylaxis and vasospastic angina: a case report. *Journal of Japanese Association for Acute Medicine* 2014; 25: 785-91.
- [13] Gomez AG, Romeo EC, Martinez S, et al.: Kounis Syndrome in a patient after administration of influenza vaccine. *Allergy* 68: 514-5. abstract. 1429.
- [14] Kundi H, Gok M, Kiziltun E, et al: A Rarely Seen Type-I Kounis Syndrome Caused By Tetanus Vaccine. *Kosuyolu Heart J* 2018; 21 (1): 82-4.
- [15] Suminobu Ito, Susumu Kusunoki, Nao Tsuchida, et al. FY 2020 Health and Labour and Welfare Policy Research Grant (Research on Emerging and Re-emerging Infectious Diseases and Immunization), an interim report of aggregated data from health observation logs in a focused survey (cohort survey) in the early phase after the start of vaccination for coronavirus disease 2019 (4) (in Japanese) [cited on May 25, 2021]; available from <https://www.mhlw.go.jp/content/10906000/000772193.pdf>